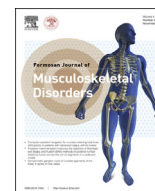



Contents lists available at ScienceDirect

Formosan Journal of Musculoskeletal Disorders

journal homepage: www.e-fjmd.com

Case Report

Locked posterior dislocation of the shoulder joint: Report of two cases

Sung-Chun Lin^{a,b}, Hsin-Pai Lee^a, Chih-Ju Chen^a, Yen-Hsuan Jean^{a,*}^a Department of Orthopedics, Pingtung Christian Hospital, Pingtung, Taiwan^b Department of Nursing, Meiho University, Pingtung, Taiwan

ARTICLE INFO

Article history:

Received 8 April 2013

Received in revised form

14 May 2013

Accepted 18 June 2013

Available online 16 November 2013

Keywords:

glenohumeral joint

Mouzopoulos sign

open reduction

posterior dislocation

shoulder joint

ABSTRACT

Posterior dislocation of the shoulder joint is very rare. Most cases are missed initially because it is difficult to diagnose using conventional radiographic images. Computed tomography (CT) is the best tool for diagnosis. We report two cases of posterior dislocation of the shoulder joint that were missed initially at another hospital. The patients presented with painful disability of the shoulder joint. Posterior dislocation of the shoulder joint was suspected after physical examination. Anteroposterior radiography was unable to confirm the diagnosis because an abnormal posterior relationship of humeral head to glenoid fossa could not be clearly identified. An axillary view was unobtainable because of severe pain and the limited joint motion available. CT showed posterior dislocation of the humeral head. The bony defect of the humeral head was incarcerated by the posterior rim of the glenoid process. Open reduction via an anterior approach was performed on both patients, who recovered with good shoulder function after rehabilitation (the Constant score of Case 1 was 85 and that of Case 2 was 75). We concluded that “Mouzopoulos sign” obtained via an anteroposterior view is helpful for the diagnosis of posterior dislocation of the shoulder joint and that CT is required for a definitive diagnosis. If the dislocation is locked and closed reduction fails, then open reduction should be carried out.

Copyright © 2013, Taiwan Orthopaedic Association. Published by Elsevier Taiwan LLC. All rights reserved.

1. Introduction

Posterior dislocation of the shoulder joint is very rare. Such a dislocation may be due to epilepsy, electrical shock, or extreme trauma (the so-called triple “E”). Most cases are missed initially because they are difficult to diagnose using conventional radiographic images alone. A detailed physical examination is important when forming an initial impression. Usually, the patient presents with a painful shoulder joint. This pain may be more severe than with an anterior dislocation. The involved shoulder joint and arm are held in adduction and with internal rotation with elevation and abduction being limited. An axillary view and a scapular “Y” view may be effective when diagnosing this problem, but may be difficult to carry out because of the shoulder’s limited range of motion and patient pain. Computed tomography (CT) is the best tool for the diagnosis of a posterior dislocation of the shoulder.

Treatment opinions and prognosis are determined according to the interval from trauma to diagnosis and the degree of bony defect affecting the humeral head. In acute simple dislocation without bony defect, a closed reduction may be done under general anesthesia with complete muscle paralysis. In neglected cases, or when a bony defect is incarcerated by the posterior rim of the glenoid process, the failure rate for closed reductions is high. An open reduction using a deltoideopectoral approach has been suggested as the preferred treatment for these patients. Laxity of the posterior capsule and a large bony defect may give rise to recurrent dislocation. Such posterior instability can be treated via open or arthroscopic posterior labral repair and capsule shift. When managing a bony defect, a number of methods have been suggested. These include subscapularis tendon transfer, lesser tuberosity transfer, reconstruction using an autogenous or allogeneous bone graft, and prosthetic arthroplasty.

We report here two cases of posterior dislocation of the shoulder joint. One was diagnosed in the acute stage, and the other was missed for 1 month. A reverse Hill–Sachs lesion was found in both cases, and both humeral heads were locked by the posterior rim of the glenoid process. In both cases, a closed reduction under general anesthesia failed and therefore open reductions were performed. The results and prognosis of these cases are described.

* Corresponding author. Department of Orthopedics, Pingtung Christian Hospital, Number 60 Da-Lan Road, Pingtung 900, Taiwan. Tel.: +886 8 7368686; fax: +886 8 7338536.

E-mail address: jean.tang@msa.hinet.net (Y.-H. Jean).

2. Case reports

2.1. Case 1

A 25-year-old man was transferred to our emergency room from a local medical clinic after he had suffered a painful disability of the right shoulder joint due to a motorcycle accident. An anteroposterior radiographic film of the shoulder showed a fracture of the lesser tuberosity of the humerus (Fig. 1A). The “Mouzopoulos sign” was positive, and posterior dislocation was suspected. The patient presented with pain, swelling, and limitation of motion of the shoulder joint. The shoulder joint and arm are held in adduction and with internal rotation. An axillary lateral view could not be obtained because of pain. CT showed posterior dislocation of the humeral head (Fig. 2A). The lesser tuberosity was avulsed by the subscapularis tendon. The bony defect of the humeral head was incarcerated by the posterior rim of the glenoid process. A closed reduction was attempted under general anesthesia but failed. Therefore, an open reduction using an anterior approach was performed. The patient was placed in a beach chair position, and the deltopectoral interval was developed. The biceps tendon was identified and, using it, we found the lesser tuberosity and the subscapularis tendon. Next, the joint capsule was dissected, and the humeral head was reduced; we then reattached the lesser tuberosity to the bony defect by fixing it with a 3.5-mm cancellous screw. After the operation, the shoulder joint was protected with a hanging sling and was kept in a neutral position for 6 weeks. Radiography of the shoulder joint to obtain anteroposterior (Fig. 3A) and axillary lateral views together with a CT scan of the shoulder joint revealed good alignment of the joint and fracture fragment. After 1 year of follow-up, the shoulder joint showed good stability, and no limitation of motion was present. The patient complained of occasional slight pain; nevertheless, he had returned to full activity. The Constant shoulder score of the right shoulder was 85, and that of the unaffected left shoulder was 100.

2.2. Case 2

A 45-year-old man visited our outpatient department because of painful disability of the left shoulder that had remained for more than 1 month after a traffic accident. Initially, he had visited a local medical clinic where radiography showed no particular abnormality and a soft tissue contusion was impressed. He received some medication, but the symptoms had persisted. He was referred to another hospital and the diagnosis remained unchanged. Stiffness

of the left shoulder joint was noted in our outpatient department. His left shoulder and arm were placed in adduction and with an internal rotation position. Radiography (anteroposterior view) of the left shoulder showed a bony defect of the humeral head (Fig. 1B). CT showed posterior dislocation of the humeral head (Fig. 2B). An open reduction using an anterior approach was performed. During the operation, instability of the glenohumeral joint was noted. Two pins were inserted that crossed the joint in order to provide temporary fixation. A reverse Hill–Sachs lesion was present, and this was managed by subscapularis tendon transfer followed by fixation using a nonabsorbable suture. After the operation, the shoulder joint was protected with a hanging sling, and the pins were removed 6 weeks later. Radiography via an anteroposterior view (Fig. 3B) and an axillary lateral view revealed good alignment of the joint. After 1 year of follow-up, the shoulder joint showed good stability, but a slight limitation of motion was noted. The patient complained of occasional slight pain; nevertheless, he had returned to full activity. The Constant shoulder score of the left shoulder was 75, whereas that of the unaffected right shoulder was 100.

3. Discussion

Posterior dislocation of the shoulder joint is an uncommon injury. Only 1–4% of all cases of dislocation of the shoulder joint are the posterior type.^{1–3} Such dislocations are usually caused by major trauma or a seizure.^{1,3} However, a posterior dislocation of the shoulder joint is difficult to diagnose by regular radiography. This event is the most common missed major joint dislocation. Radiography via the axillary lateral view or the scapular “Y” view may be useful for diagnosis, but are difficult to obtain because of pain and the limited abduction of the shoulder that is available after the acute trauma.¹ CT is useful as a way of obtaining a final diagnosis, especially when estimating the size of the bone defect that affects the humeral head.⁴

Mouzopoulos⁵ described a radiographic sign visible in the anteroposterior view of the shoulder joint that helps to identify a posterior dislocation. The sign is produced by the projections of the greater and lesser tuberosity borders, and these form a letter “M” in the anteroposterior view of a shoulder joint when there is a posterior dislocation. In the neutral position, these borders are two vertical lines, and an M cannot be seen. A posterior dislocation must be carefully differentiated from a maximal internally rotated shoulder without dislocation, which may produce a false-positive Mouzopoulos sign.

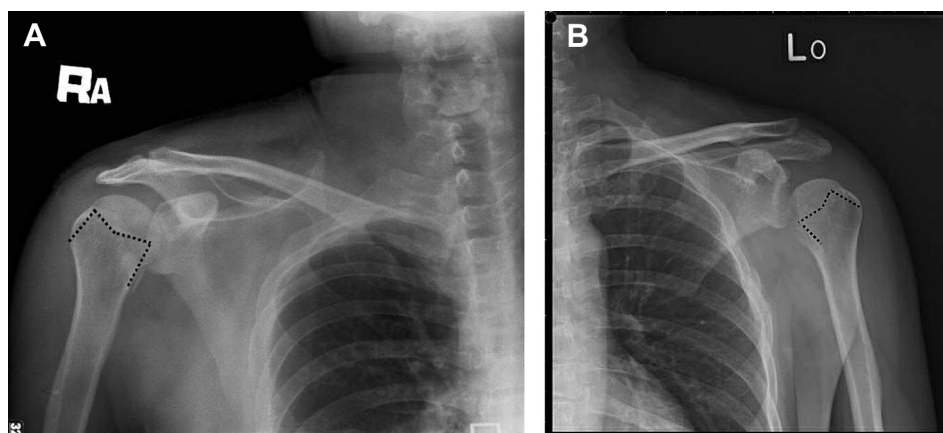


Fig. 1. (A) Radiograph (anteroposterior view) of the right shoulder of Case 1 on arrival at the emergency room showing a fracture of the lesser tuberosity. (B) Radiograph (anteroposterior view) of the left shoulder of Case 2. The projections of the greater and lesser tuberosity borders form the letter “M”. The Mouzopoulos sign is positive in both cases.

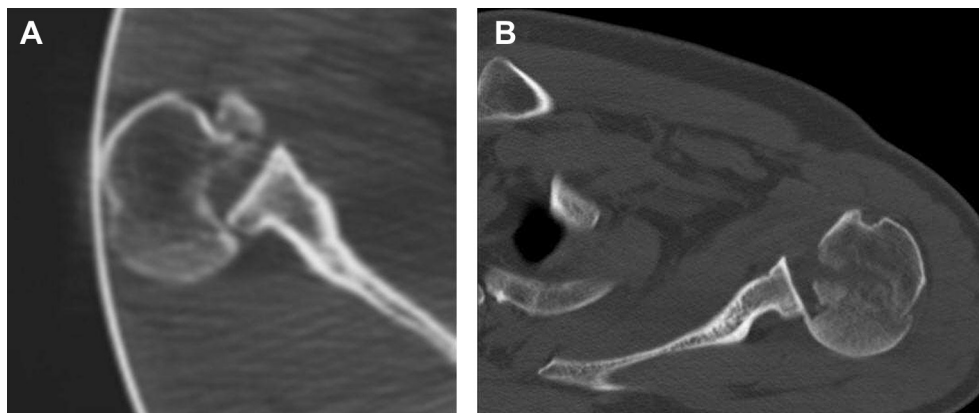


Fig. 2. Computed tomography (CT) confirms posterior dislocations of the shoulder joint and their association with a reverse Hill–Sachs lesion. (A) CT of the right shoulder of Case 1. (B) CT of the left shoulder of Case 2.

The other reported “signs” of posterior dislocation of the shoulder joint include the “light bulb sign”, the “rim sign”, the “trough line sign”, and the “absence of normal half-moon overlap”. The light bulb sign resulted from the fixed internally rotated humeral head that now appears circular. This sign may be absent because of the overlap of the humeral head and the glenoid process. When the two cases presented here were examined, the light bulb sign was absent from both patients. The rim sign means the presence of a wider joint space, namely, more than 6 mm, in a radiograph of a posterior dislocation. However, hemoarthrosis or septic arthritis may result in a false positive, and a large bony defect leading to a humeral head medial shift toward the glenoid process will result in a false negative. When the two cases presented here were examined, the rim sign was absent from both patients. The trough line sign means that an impaction fracture of the humeral head can be detected. This sign was negative for Case 1, but positive for Case 2; nevertheless, a reverse Hill–Sac lesion was found to be present in both patients. The last sign is the absence of normal half-moon overlap. This sign can be seen in a normal radiograph (a false positive situation) and can also be absent when there is a posterior dislocation of the shoulder joint (a false negative situation).⁵ When these two patients were examined, the sign was positive for Case 2. The Mouzopoulos sign has been found to occur more frequently than the other signs in previous reports. In our cases, the Mouzopoulos sign was seen in both patients when their initial anteroposterior radiographic views were examined.

The decision as to how to treat a posterior dislocation of the shoulder depends on the interval between trauma and diagnosis together with the degree of the bony defect of the humeral head (reverse Hill–Sachs lesion) that is present. In acute cases with a small defect, a closed reduction should be attempted under general anesthesia and muscle relaxation. In the literature, the success rate for closed reductions is about 50%.⁶ Furthermore, Rezazadeh and Vosoughi⁷ reported a successful closed reduction of an acute posterior dislocation of shoulder joint when there was a medium-size defect (25–50%); this was carried out under general anesthesia. The appropriate method when performing a closed reduction is a procedure similar to the Hippocratic technique. The person carrying out the reduction applies longitudinal and lateral traction to the patient’s arm, then gently rotates it. Once the humeral head is unlocked, the shoulder joint can be reduced by anterior lifting and external rotation. The Kocher’s technique should not be attempted because this approach does not work with a posterior dislocation and may give rise to an iatrogenic fracture of the humeral head or glenoid process.⁸ After the joint is reduced, an external rotation sling or brace should be applied for 4 weeks. If closed reduction fails or the dislocation has been missed for more than 3 weeks, an open reduction needs to be carried out. The procedure is usually performed using an anterior deltoideopectoral approach. During the operation, the long head of biceps tendon can be used as a landmark to identify the displaced lesser tuberosity or subscapularis tendon. After retraction of the lesser tuberosity and the

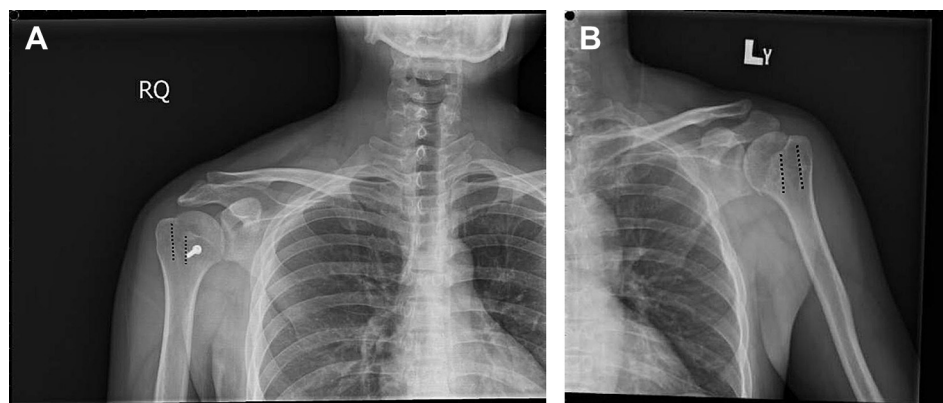


Fig. 3. (A) Radiograph (anteroposterior view) of the right shoulder of Case 1 after the operation to reduce the shoulder dislocation. (B) Radiograph (anteroposterior view) of the left shoulder of Case 2 at final follow-up. The projection of the greater and lesser tuberosity borders form two vertical lines and an “M” cannot be seen.

subscapularis tendon, the glenoid process is exposed, and the humeral head can be pulled laterally and reduced into the glenoid fossa.

Posterior dislocation of the shoulder is usually associated with a reverse Hill–Sachs lesion. This is an impression defect of the anteromedial aspect of the humeral head and is caused by an avulsion fracture of the lesser tuberosity, which is incarcerated over the posterior rim of the glenoid process.⁹ This event results in loss of abduction and causes forward elevation; such occurrences can be the cause of a closed reduction failing. If the bone defect is less than 40%, transfer of the lesser tuberosity with the subscapularis tendon to fill the defect is suggested.^{3,4} Both of our cases were noted to have reverse Hill–Sachs lesions. During the operation, we found that the fracture fragment was pulled out of place by the subscapularis tendon. After the reduction of the humeral head, the fragment and tendon were reattached to the bony defect. In Case 1, the fragment was large enough to be fixed with a screw. In Case 2, the fragment was too small to be fixed with a screw so a nonabsorbable suture was used for fixation.

If the reverse Hill–Sachs lesion is too large or no fracture fragment is available, a structural bone graft (autogenous or allogeneous)^{1,10} may be used for reconstruction. If the defect of the articular surface is more than 50% of the head, the best choice for treatment is a prosthetic replacement.^{4,11–13}

We used the Constant score (Constant–Murley Shoulder Outcome Score)² to evaluate the treatment outcomes. The first patient was younger and was treated in the acute stage of his dislocation; he had an excellent outcome (Constant score 85). Treatment of the other patient was delayed until 1 month after the injury. A slight limitation of motion of the shoulder joint was noted after 1 year of rehabilitation (Constant score 75). However, the muscle power in the affected limb was completely recovered and the patient had returned to work and to his daily activities without any limitations.

In conclusion, posterior dislocation of the shoulder joint is a rare injury and can be easily missed in the emergency room. A detailed

physical examination should be carried out when such a dislocation is suspected. The presence of the Mouzopoulos sign in the anteroposterior view may be helpful, but CT is required for a definitive diagnosis. Posterior dislocation of the shoulder joint should be treated as soon as possible via a closed reduction under general anesthesia. If the dislocation is locked and a closed reduction fails, then an open reduction should be carried out.

References

1. T.D.W. Alta, W.J. Willems. Bilateral posterior fracture–dislocation of the shoulder managed by allograft reconstruction of the segmental defect: report of two cases. *Eur J Orthop Surg Traumatol* 18 (2008) 381–385.
2. C.R. Constant, A.H.G. Murley. A clinical method of functional assessment of the shoulder. *Clin Orthop Rel Res* 214 (1987) 160–164.
3. M.I. Iosifidis, I. Giannoulis, S. Traios, G. Giantsis. Simultaneous bilateral posterior dislocation of the shoulder: diagnostic problems and management—a case report. *Knee Surg Sports Traumatol Arthrosc* 14 (2006) 766–770.
4. A. Castagna, G.D. Rose, M. Borroni, N. Markopoulos, M. Conti, L. Maradei, R. Garofalo. Modified MacLaughlin procedure in the treatment of neglected posterior dislocation of the shoulder. *Musculoskelet Surg* 93 (2009) S1–S5.
5. G. Mouzopoulos. The “Mouzopoulos” sign: a radiographic sign of posterior shoulder dislocation. *Emerg Radiol* 17 (2010) 317–320.
6. R.J. Hawkins, C.S. Neer, R.M. Pianta, F.X. Mendoza. Locked posterior dislocation of the shoulder. *J Bone Joint Surg Am* 69 (1987) 9–18.
7. S. Rezazadeh, A.R. Vosoughi. Closed reduction of bilateral posterior shoulder dislocation with medium impression defect of the humeral head: a case report and review of its treatment. *Case Rep Med* 2011 (2011) 124581.
8. T. Baring, P.M. Ahrens. Latrogenic glenoid rim fracture during manipulation of a posterior dislocation. *Int J Shoulder Surg* 6 (2012) 99–100.
9. N. Cicak. Aspects of current management: posterior dislocation of the shoulder. *J Bone Joint Surg Br* 86 (2004) 324–332.
10. A. Ivkovic, I. Boric, N. Cicak. One-stage operation for locked bilateral posterior dislocation of the shoulder. *J Bone Joint Surg Br* 89 (2007) 825–828.
11. I. Gavrilidis, P. Magosch, S. Lichtenberg, P. Habermeyer, J. Kircher. Chronic locked posterior shoulder dislocation with severe head involvement. *Int Orthop (SICOT)* 34 (2010) 79–84.
12. B.J. Singh, S. Sinha, C.A. Brooks. Bilateral posterior fracture dislocation of shoulder: a case report. *Eur J Orthop Surg Traumatol* 14 (2004) 116–118.
13. J.W. Sperling, M. Pring, S.A. Antuna, R.H. Cofield. Shoulder arthroplasty for locked posterior dislocation of the shoulder. *J Shoulder Elbow Surg* 13 (2004) 522–527.